

Successful radiofrequency catheter ablation for ventricular tachycardia of a 2.9 kg infant with Ebstein's anomaly

Naoki Takeshita^{1*}, Yo Kajiyama¹, Yuma Morishita¹, Toshiyuki Itoi¹, Masaaki Yamagishi², and Tsugutoshi Suzuki³

¹Department of Pediatric Cardiology and Nephrology, Kyoto Prefectural University of Medicine, Kajii-cho, Kawaramachi-Hirokoji, Kamigyo-ku, Kyoto 602-8566, Japan;

²Department of Pediatric Cardiovascular Surgery, Kyoto Prefectural University of Medicine, Kajii-cho, Kawaramachi-Hirokoji, Kamigyo-ku, Kyoto 602-8566, Japan; and

³Department of Pediatric Electrophysiology, Pediatric Medical Care Center, Osaka City General Hospital, 2-13-22, Miyakojima-hondori, Miyakojima-ku, Osaka 534-0021, Japan

* Corresponding author. Tel: +81 75 251 5832; fax: +81 75 251 5833, E-mail address: naoki-t@koto.kpu-m.ac.jp

We report a successful case of radiofrequency catheter ablation for uncontrollable ventricular tachycardia in a 2.9 kg, 1-month-old infant with Ebstein's anomaly.

Case

A 39-day-old female infant with complex congenital heart defects (CHDs) developed critical VT. The patient was originally referred by the obstetric section for Ebstein's anomaly, pulmonary atresia, atrial septal defect, and patent ductus arteriosus. She had a severely dysplastic tricuspid valve and an almost atrialized right ventricle (RV); therefore, she was classified as Carpentier's type D. Her ductus arteriosus was maintained by continuous infusion of prostaglandin E1 until the Blalock-Taussig shunt operation.

An electrocardiogram showed repeated sinus rhythm and spontaneous wide QRS tachycardia ranging from 200 to 240 bpm (Figure 1A). We observed atrioventricular dissociation and fusion beats of a hybrid complex of the supraventricular and ventricular

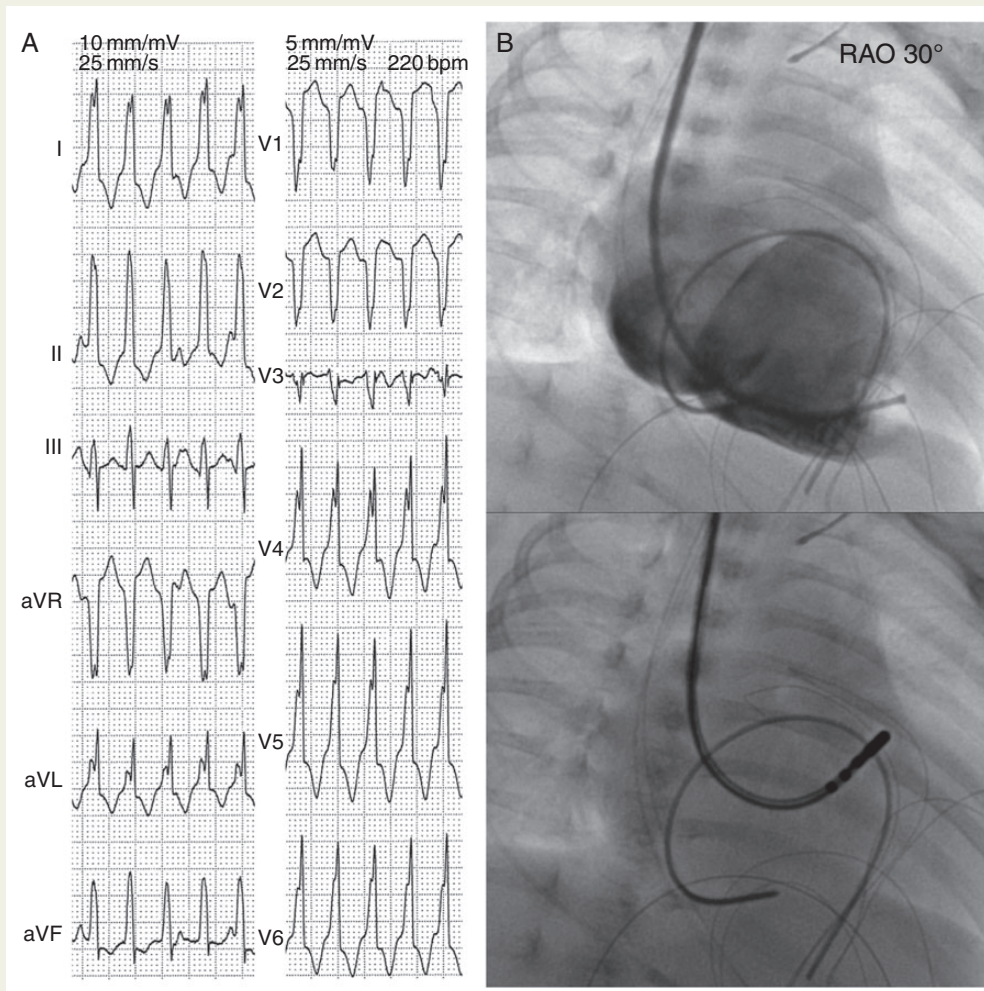


Figure 1 (A) Twelve-lead electrocardiogram showing ventricular tachycardia with atrioventricular dissociation. (B) Fluoroscopic image of the right ventriculogram and the ablation catheter at the focus of the ventricular tachycardia in the right anterior oblique at 30°.

impulses. Based on the characteristic electrocardiographic features, we assumed that the arrhythmia was a focal VT originating from the right ventricle. We attempted the following therapies and found them ineffective: (i) pharmacological therapies including lidocaine (1.7 mg/kg/h), flecainide (1.7 mg/kg/dose), and amiodarone (12 mg/kg/day) and (ii) overdrive pacing with pacing leads surgically inserted to the right atrium and RV. Her cardiovascular status gradually deteriorated, and we decided to perform RFCA for the VT. The procedure took place under general anaesthesia and mechanical ventilation when she was 46 days old. At that time, her body weight was only 2.9 kg. We approached the RV via the right internal jugular vein with 5-Fr sheath puncture. The earliest activation site was identified using bipolar electrograms. Radiofrequency catheter ablation up to 60°C and 20 W in temperature control mode for 60 s on the earliest activation site we found at the outflow tract of the RV terminated the arrhythmia immediately (Figure 1B). Ventricular tachycardia recurred at 62 days of age and was terminated in the same ablation technique and settings as the first session.

Three weeks later, after the stabilization of her general status, the following surgeries were performed: Starnes' procedure, RV exclusion, division of the ductus arteriosus, construction of the Blalock-Taussig shunt, and intraoperative cryoablation for residual muscle of the excluded RV. During 7 months of observation post surgery, she did not manifest any arrhythmic events. She is waiting for the next surgical intervention, Glenn procedure, without any anti-arrhythmic agents.

Discussion

Radiofrequency catheter ablation plays an important role in the management of arrhythmias in adults. This procedure is invaluable even in the paediatric population. However, interventionists are often constrained by technical restrictions such as limited number and size of catheters, and the smaller size of the heart itself. Furthermore, CHDs make catheter interventions more difficult; hence, pharmacological treatment is preferable to catheter ablation in small infants. In this case, however, RFCA was attempted as the final option because the pharmacological and pacing therapies could not manage the cardiovascular status.

Ebstein's anomaly sometimes presents with electrical conduction abnormalities and supraventricular arrhythmia, typically atrioventricular reciprocating tachycardia associated with the wolff-parkinson-white (WPW) syndrome. Although the atrialized RV would mediate arrhythmias literally,^{1,2} we found only a few reports of Ebstein's anomaly associated with uncontrollable VT.

Conflict of interest: none declared.

References

1. Attenhofer Jost CH, Connolly HM, Edwards WD, Hayes D, Warnes CA, Danielson GK. Ebstein's anomaly – review of a multifaceted congenital cardiac condition. *Swiss Med Wkly* 2005;**135**:269–81.
2. Kastor JA, Goldreyer BN, Josephson ME, Perloff JK, Scharf DL, Manchester JH *et al.* Electrophysiologic characteristics of Ebstein's anomaly of the tricuspid valve. *Circulation* 1975;**52**:987–95.